

J Vet Diagn Invest 18:303–306 (2006)

Bilateral cystic rete testis in an alpaca (*Lama pacos*)

Michelle A. Kutzler,¹ Michelle Shoemaker, Beth A. Valentine, Robert J. Bildfell, Susan J. Tornquist

Abstract. A 9-year-old intact male alpaca (*Lama pacos*) was examined because of marked enlargement of the left scrotum. Ultrasound examination revealed a thin-walled anechoic structure in the area of the left testis. Aspirated fluid contained spermatozoa, many of which had abnormal morphology. Castration was performed and the left testis was markedly enlarged with a clear fluid-filled cyst. The cyst was lined by a single layer of squamous to cuboidal epithelial cells consistent with those originating from rete testis. The right testis was of a comparable size and shape to that of normal alpaca testis, but the rete testis was mildly to moderately dilated. Additional findings included chronic inflammation of the right testis and epididymis and epididymal fibrosis with ductal hyperplasia on the left. The diagnosis was bilateral cystic rete testis, most likely secondary to chronic inflammation.

Key words: Camelid; rete testis; testicular cyst.

From the Departments of Clinical Sciences (Kutzler, Shoemaker) and Biomedical Sciences and Veterinary Diagnostic Laboratory (Valentine, Bildfell, Tomquist), Oregon State University, Corvallis, OR 97331.

¹Corresponding Author: Dr. Michelle Kutzler, 105 Magruder Hall, Oregon State University, Corvallis, OR 97331.

A 9-year-old intact male Huacaya alpaca (*Lama pacos*) was presented to the veterinary teaching hospital at Oregon State University with enlargement of the left scrotum. The enlargement had been evident when the animal was acquired 4 months before presentation. No information, before this time, is available. The alpaca had sired several crias; the last successful breeding was 1 year previously. It

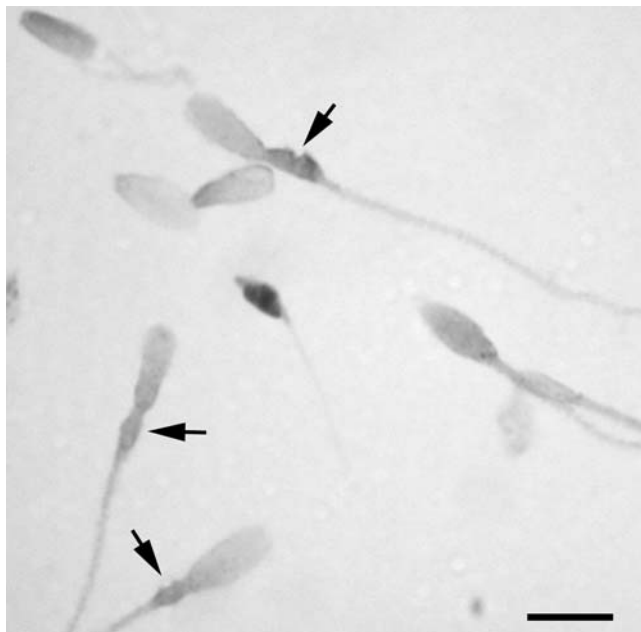


Figure 1. Cytospin preparation of a fine needle aspirate from the cystic left testis of an alpaca. Spermatozoa with swollen, vacuolated midpieces (arrows) are seen. Wrights stain. Bar = 10 μ m.

had not been bred since that time. The left scrotum had increased significantly in size 2 days before presentation. There was a large fluctuant nonpainful swelling on the left scrotum and the left testis was not palpable. Ultrasound examination revealed a homogeneous testis on the right and a thin-walled, anechoic fluid-filled structure on the left. Normal left testis was not identified.

A fine needle aspirate of the left scrotum produced 12 ml of clear fluid. Analysis of this fluid revealed a transudate (<1 g of protein/dl) with very low cellularity (78 nucleated cells/ μ l) and a large number of spermatozoa with abnormal morphology, primarily swollen, vacuolated midpieces (Fig. 1). The nucleated cells included a small number of macrophages, a few small lymphocytes, and occasional neutrophils and epithelial cells. Aerobic bacterial culture produced no growth. A presumptive diagnosis of a cystic left testis was made.

General anesthesia was induced and castration was performed. The incision at the left scrotum inadvertently punctured the underlying tunica releasing approximately 100 ml of watery fluid. The left testis consisted of a thin rim (0.3 to 0.4 cm thick) of markedly compressed tissue, measuring 10 \times 5 \times 5 cm (Fig. 2). On section, the left testis consisted of an outer rim of orange-tan tissue surrounding a cystic cavity filled with fibrous strands of pale tissue. The left epididymis was small and difficult to identify. The right testis was of normal size and shape and measured 4.0 \times 2.5 \times 2.5 cm (Fig. 2), with a normal appearing epididymis. On sagittal section the right testis contained an irregular central cystic area (0.6 \times 0.4 \times 0.4 cm) in the caudal portion of the testis surrounded by grossly unremarkable testicular tissue. Both gonads were fixed in 10% neutral buffered formalin and multiple

samples were paraffin embedded, sectioned at 6 μ m, and stained with hematoxylin and eosin.

On microscopic examination, the outer cystic left testis was composed of a thin rim of seminiferous tubules. Some tubules exhibited normal spermatogenic maturation, but maturation arrest with scattered multinucleate cells was visible in others. Cyst luminal epithelium was not apparent in many areas, but when present, consisted of a single layer of cuboidal to markedly attenuated epithelium. The cyst wall included a band of mature collagen forming short papillary projections. The head of the epididymis contained ducts of varying size, normal to hyperplastic, with markedly increased interstitial connective tissue and no intraluminal spermatozoa. Occasional ducts within the hyperplastic zone were lined by approximately 3 to 4 layers of cuboidal epithelium with prominent vacuolated cytoplasm. Efferent ductules and interstitial lymphatics were distended. The histologic diagnosis was severe cystic rete testis with epididymal fibrosis and ductal epithelial hyperplasia.

On microscopic examination, the right testis had normal seminiferous tubules with normal spermatogenic maturation. The cystic zone had irregular thin branching trabeculae lined by a single layer of cuboidal epithelium with an underlying thin layer of collagenous stroma (Fig. 3). There were scattered lymphoid aggregates within the stroma of the cystic area occasionally extending into the lumen of the cyst. An area of intense lymphocytic, neutrophilic, and histiocytic inflammation involving the interstitium and the seminiferous tubules was present adjacent to the cystic area. Seminiferous tubules in this area often exhibited degenerative change such as the presence of multinucleate cells and lack of spermatid maturation. The interstitium at the head of the epididymis contained an aggregate of sperm with intense associated pyogranulomatous inflammation. Elsewhere, inflammation was minimal to absent, and normal spermatozoa were present within ducts. No microorganisms were associated with the inflammation. The histologic diagnosis was mild to moderate cystic dilation of the right rete testis with locally extensive chronic nonsuppurative orchitis and epididymitis and early epididymal sperm granuloma formation.

The rete testis is a thin-walled convoluted network of tubules lined by a single layer of simple cuboidal epithelium and supported by fine collagenous stroma.^{12,17} The rete testis is in the mediastinum of the testis and serves as the conduit for maturing spermatozoa passing from the seminiferous tubules to the efferent ductules, which join with the epididymal duct at the head of the epididymis.¹² The rete testis transforms testicular fluid by protein reabsorption and sperm phagocytosis.⁸ Examination of normal testes removed from sexually mature alpacas and llamas (*Lama glama*) indicates that the highly convoluted rete testis is grossly visible in the central caudal testis, but cystic dilatation of the rete testis is not normally present.

Testicular cysts are relatively common in alpacas, with a reported incidence of approximately 14.5%.¹⁷ The majority of cysts reported are derived from paramesonephric duct remnants. One cyst was described involving the entire testis, similar to this case, but no histopathology was performed to determine the origin.¹⁷

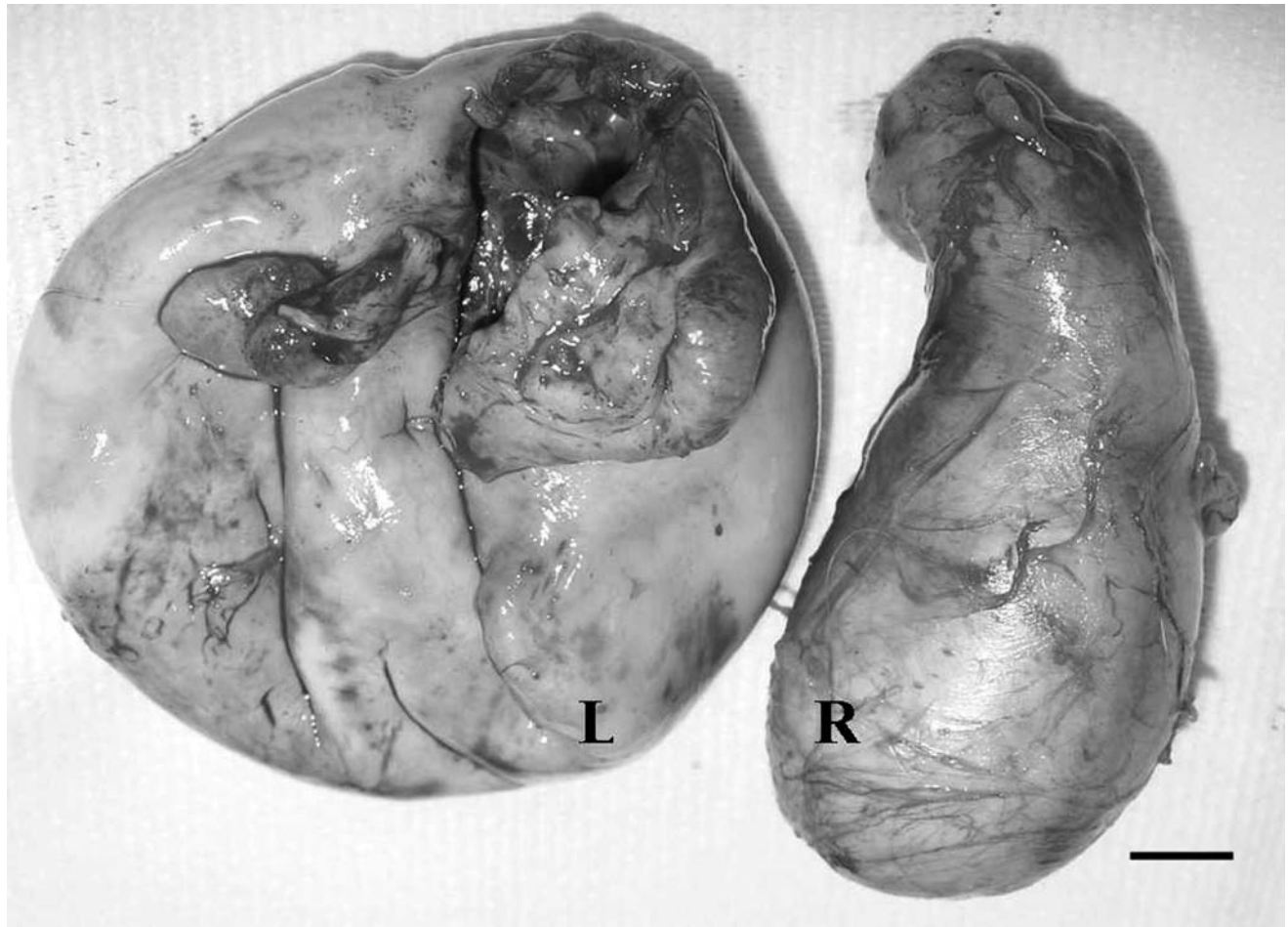


Figure 2. The testes of an alpaca following castration. The left testis (L) is markedly enlarged and globose. The right testis (R) is of normal size and shape. Bar = 1 cm.

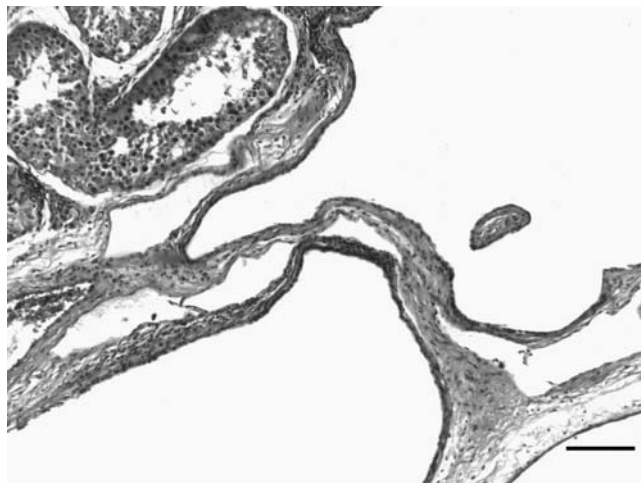


Figure 3. Photomicrograph of the right testis of an alpaca. There is mild to moderate dilation of the rete testis but the trabecular appearance is maintained. The lining epithelium and the adjacent seminiferous tubules are normal. HE. Bar = 100 μ m.

In men, cystic rete testis can be congenital or acquired. Developmental abnormalities leading to cystic dysgenesis of the rete testis are rare.⁶ The lesion develops during the fifth week of gestation, due to a malformation between the efferent ductules derived from the mesonephros and the rete testis tubules derived from the gonadal blastema.⁶ Cystic dysgenesis of the rete testis is commonly observed in conjunction with ipsilateral agenesis of the kidney.⁶ No attempt was made to determine whether the alpaca in this report had renal agenesis. Acquired cystic rete testis is more common in men, with an incidence of 1.6% in one report.¹⁴ Cystic rete testis may be found incidentally in men during scrotal ultrasonography and can occur unilaterally or bilaterally.¹⁵ Acquired cystic rete testis can result from multiple etiologies: partial or complete mechanical obstruction within the head of the epididymis by an epididymal or spermatic cord tumor, chronic epididymitis, traumatic hemocele, cystadenoma of the testis, or intratesticular spermatic duct cyst.¹⁴ Mechanical obstruction may develop secondary to accumulation of crystalline calcium oxalate deposits in the lumen of the rete testis and efferent ducts as a result of chronic renal insufficiency¹³ or secondary to the accumulation of degenerate germ cells in the aged testis.⁹

Atrophy is the most common epididymal lesion associated with cystic rete testis in men.¹⁴ In elderly men, ischemia due to vascular disease is a common cause of cystic degeneration of the seminiferous tubules.¹⁴

Cystic rete testis appears to be very rare in domestic animals, there have been only 3 previous reports in the literature.^{7,16} Unilateral cystic rete testis in a young cat and a mature red fox have been described.⁷ The cat was believed to have had a congenital defect, while the fox was thought to have blockage of the efferent ducts by a seminoma.⁷ Cystic rete testis has been reported in the cryptorchid testis of a horse.¹⁶

Any process that disrupts spermatogenesis, either congenital or acquired, will result in abnormal sperm development. The most commonly observed abnormal morphologic finding in the testicular aspirate from this animal was a swollen, vacuolated midpiece. In cattle, focal thickening of the midpiece is referred to as a pseudodroplet defect.^{1,2} In one study, the incidence of the pseudodroplet defect in bovine ejaculates ranged from 7 to 26% and correlated positively with increased age.² In camelids, ejaculates from fertile males often contain a high percentage of sperm with abnormal morphology (up to 65%), particularly abnormalities of the head and midpiece.^{3,10,11} In one study, transmission electron microscopy showed the thickened midpiece was an accumulation of loose coiled membranes on the surface of the mitochondrial helix.¹⁰ It is not known if the alpaca described was fertile at the time of castration but it had sired several offspring in previous years.

Ultrasonographic features of cystic rete testis have not been reported previously in animals. The normal ultrasonographic appearance of the rete testis is a small echogenic structure communicating between the mediastinum and the epididymal head.¹⁵ The ultrasonographic findings in the left testis of this alpaca were similar to those reported in men with cystic rete testis, who vary from having a collection of small, irregular hypoechoic structures in confluence with the mediastinum to that of a single anechoic structure replacing the mediastinum and compressing the testicular parenchyma into a thin rim.^{4,5} A limited ultrasonographic examination of the grossly normal right testis of the alpaca, did not identify the less severely dilated right rete testis.

To the authors' knowledge, this is the first report of cystic rete testis in a camelid, as well as the first report of bilateral cystic rete testis in a domestic animal. Given this animal's age, the history of successful breeding, and the presence of bilateral epididymal damage, an acquired mechanical obstruction leading to rete testis dilation is suspected, but a developmental defect causing slowly

progressive dilation of the rete testis with secondary inflammation cannot be entirely ruled out.

Acknowledgements. The authors thank Dr. Barry Cooper for providing photographic assistance and Dr. Pat Long for providing diagnostic specimens.

References

1. Barth AD, Oko RJ: 1989, *In: Abnormal Morphology of Bovine Spermatozoa*, pp. 225–226, 260–261. Iowa State University Press, Ames, IA.
2. Blom E: 1968, A new sperm defect - "pseudo-droplets" - in the middle piece of the bull sperm. *Nord Vet Med* 20:279–283.
3. Bravo PW, Skidmore JA, Zhao XX: 2000, Reproductive aspects and storage of semen in Camelidae. *Anim Reprod Sci* 62:173–193.
4. Burrus JK, Lockhart ME, Kenney PJ, Kolettis PN: 2002, Cystic ectasia of the rete testis: clinical and radiographic features. *J Urol* 168:1436–1438.
5. Dogra VS, Gottlieb RH, Rubens DJ, Liao L: 2001, Benign intratesticular cystic lesions: US features: 2001. *Radiographics* 21:S273–S281.
6. Eberli D, Gretener H, Dommann-Scherrer C, et al.: 2002, Cystic dysplasia of the rete testis: a very rare paediatric tumor of the testis. *Urol Int* 69:1–6.
7. Gelberg HB, McEntee M: 1983, Cystic rete testis in a cat and fox. *Vet Pathol* 20:634–636.
8. Holstein AF: 1978, Spermatophagy in the seminiferous tubules and excurrent ducts of the testis in Rhesus monkey and in man. *Andrologia* 10:331–352.
9. Itoh M, Li XQ, Miyamoto K, Takeuchi Y: 1999, Degeneration of the seminiferous epithelium with ageing is a cause of spermatoceles? *Int J Androl* 22:91–96.
10. James E, Stang N, Kutzler M: 2005, *In: Proceedings from the 7th Annual Northwest Reproductive Sciences Symposium*. Seattle, WA., [Abstr.]
11. Lichtenwalner AB, Woods GL, Weber JA: 1996, Seminal collection, seminal characteristics and pattern of ejaculation in llamas. *Theriogenology* 46:293–305.
12. Nickel R, Schummer A, Seiferle E: 1979, *In: The Viscera of the Domestic Mammals*, 2nd ed., pp. 304–324. Springer-Verlag, New York, NY.
13. Nistal M, Jimenez-Heffernan JA, Garcia-Viera M, Paniagua R: 1996, Cystic transformation and calcium oxalate deposits in rete testis and efferent ducts in dialysis patients. *Human Pathol* 27:336–341.
14. Nistal M, Mate A, Paniagua R: 1996, Cystic transformation of the rete testis. *Am J Surg Pathol* 20:1231–1239.
15. Pavlica P, Ramini R, Barozzi L: 1994, Tubular ectasia of the rete testis. The echographic aspects. *Radiol Med (Torino)* 87:493–497.
16. Schumacher J, Lenz SD, Walker W: 1994, Cystic rete testis associated with cryptorchidism in a horse. *Vet Pathol* 31:115–117.
17. Sumar J: 1983, Studies of reproductive pathology in alpacas. PhD Thesis. Swedish University of Agricultural Sciences. Uppsala, Sweden.